

Hirsutism following the use of bimatoprost eyedrops for glaucoma

Subashini Kaliaperumal, Indu Govindaraj, Praveen Kumar Kopparapu, Shashi Ahuja

Department of Ophthalmology, Jawaharlal Institute of Postgraduate Medical Education and Research, Puducherry, Tamil Nadu, India

Received: 16-05-2013

Revised: 22-06-2013

Accepted: 30-11-2013

ABSTRACT

Prostaglandin F2 alpha (PGF2 α) analogues including bimatoprost are often the first line drugs used in the treatment of glaucoma. We present a case of a 62-year-old female patient who was started on bimatoprost in both the eyes for primary open angle glaucoma. The intraocular pressures reached the target level but she developed hair growth over the chin and upper lip after six months of commencing of the treatment. The regional hypertrichosis did not reduce much after stopping the drug. Hirsutism is a potential side effect of prostaglandin analogues which has rarely been reported. Doctors and patients need to be aware of this noticeable and unwanted side effect. The effect seems to occur in patients already having few non-vellus hairs in these areas.

Key words: Bimatoprost, hirsutism, prostaglandin analogue, side effects

INTRODUCTION

Prostaglandin F2 alpha (PGF2 α) analogues are often the most effective class of newer antiglaucoma medications available in the market and hence are used as first line topical agents in the treatment of glaucoma. Bimatoprost is a synthetic prostamide structurally similar to other prostaglandin analogs, including latanoprost, travoprost and unoprostone.^[1] The free acids of all prostaglandin analogues (PGAs) reduce intraocular pressure (IOP) by their effects on ciliary muscle relaxation and remodeling of extracellular matrix thereby enhancing uveoscleral and trabecular outflow.^[2] Conjunctival hyperemia,

hypertrichosis of the lashes, periocular hyperpigmentation and iris pigmentation are well known ocular side effects of prostaglandin analogues. Anecdotal reports of cystoid macular edema, iris cysts, anterior uveitis and herpes simplex have been noted in patients on PGF2 α drugs.^[2] There have been reports of periorbital fat atrophy and deepening of the superior sulcus following their use.^[3] Bimatoprost and other prostaglandin analogues can increase thickness and length of lashes, produce additional lash rows and can convert vellus to terminal hairs in canthal areas and in regions adjacent to lash rows.^[4] Nevertheless, hirsutism as a side effect of any of the PG analogues is rarely seen.

CASE REPORT

A 62-year-old female, a known patient of primary open angle glaucoma presented with IOP of 23 mmHg in right eye (RE) and 22 mmHg in the left eye (LE). She had been on 0.5% timolol maleate eyedrops for three years prior to presentation but was lost to follow-up for more than a year. The cupping was 0.7 RE and 0.8 LE with thin neuroretinal rims inferiorly.

Access this article online

Quick Response Code:



Website:

www.jpharmacol.com

DOI:

10.4103/0976-500X.136110

Address for correspondence:

Subashini Kaliaperumal, 8A, Balaji Street, Tagore Nagar, Jeevanandapuram, Puducherry - 605 008, Tamil Nadu, India.

E-mail: subadoc@gmail.com

Since the target IOP was not attained, she was switched to bimatoprost (Lumigan 0.03%, Allergan) eyedrops. At six months review, she had some lash growth and conjunctival hyperemia. In addition to lash growth, the patient had hair growth from the chin and above the upper lip which was extensive enough to be socially embarrassing. Though the patient always had minimal non-vellus hair growth in the same regions, this had increased in number, thickness and length after starting bimatoprost [Figure 1]. The patient's IOPs were maintained at target level. The patient's medical history was unremarkable with no intake of any other drugs. The prostaglandin analogue was stopped and instead dorzolamide and timolol fixed combination was started. When the patient came seven months later, the hair growth did not show significant reduction [Figure 2].

DISCUSSION

The systemic exposure from ocular dosing with prostaglandin analogues including bimatoprost is low.^[2] It has been seen that after one drop of bimatoprost 0.03% in each eye (9 µg of drug), the maximum plasma concentration of bimatoprost was approximately 10^{-10} M (Lumigan product info, Allergan). The levels peaked within 10 minutes of dosing and became undetectable within 1.5 h. The values of the mean maximum blood concentration and area under the curve were similar (0.08 ng/mL and 0.09 ng/h/mL respectively on days 7 and 14).^[1] Bimatoprost did not accumulate in the blood over time and the elderly and young patients had a similar safety profile. Upper respiratory tract infection, headaches, abnormal liver function tests, and asthenia are some systemic adverse events which have been reported after the treatment with bimatoprost.^[5,6]

Hirsutism is defined as the growth of terminal hair with masculine characteristics and pattern in women, whereas hypertrichosis describes the growth of terminal from vellus hair. Hirsutism and hypertrichosis may be associated with

drugs that include cyclosporin, minoxidil, diazoxide, erythropoietin, calcium-channel blockers, benoxaprofen, and tretinoin.^[7,8] Mild hirsutism can often occur in older women because they produce higher levels of testosterone than usual. Our patient was screened for the aforementioned causes and was found to be normal.

Though hypertrichosis of lashes is a regular side effect, hirsutism as seen in our patient is very rare. The patient had a few terminal (non-vellus) hairs in the chin area and upper lip before commencing bimatoprost but they have increased in number, thickness and length after the treatment. Hypertrichosis of eyelashes is reported to be more and occurs earlier with bimatoprost. The resting follicles (telogen phase) are stimulated to growing follicles (anagen phase) due to interaction of the drugs with the prostanoid receptors in the hair follicle. The anagen phase of eyelashes may be prolonged which could increase their length. This same mechanism would apply for localized hypertrichosis elsewhere.

Hypertrichosis of lashes is now a desirable outcome for patients who prefer to have longer eyelashes. Latisse (Allergan Inc. Irvine, CA) which is bimatoprost 0.03% solution and identical to the ophthalmic solution for glaucoma treatment, was approved by the US Food and Drug Administration (FDA) for increasing eyelash length, thickness and darkness in patients with hypotrichosis of the eyelashes. Although bimatoprost is effective in promoting increased growth of healthy eyelashes and adnexal hairs, it may not be effective in patients with eyelash alopecia areata and in patients with eyelash loss secondary to radiation or chemotherapy. It seems that prostaglandin or prostamide analogs are only effective in promoting eyelash regrowth in patients with a mild form of eyelash alopecia areata.^[9] Apparently, an intact hair follicle is necessary for exogenous prostaglandin analogs to be effective in the promotion of hair growth. This reasoning explains why our patient (who already had few terminal hairs

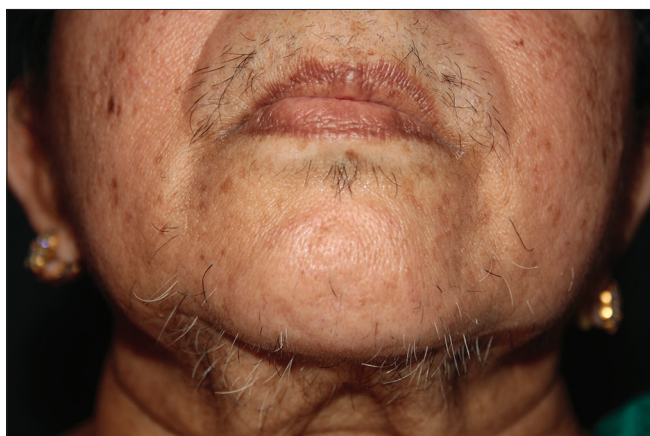

Figure 1: Hair growth around the chin and lip following the use of bimatoprost eyedrops

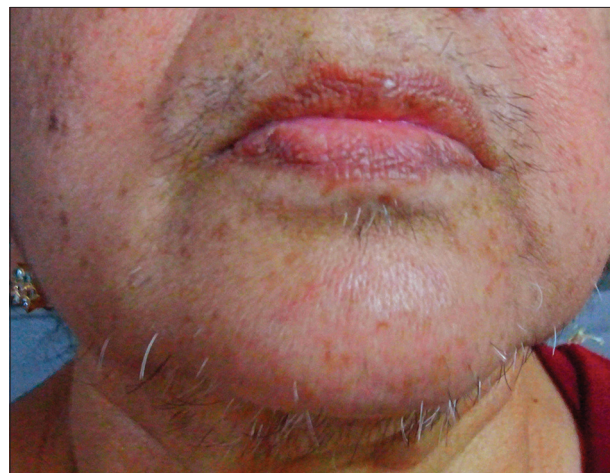

Figure 2: Slight reduction in the hair growth around the chin and lip after stopping bimatoprost eyedrops

near the chin and lip) developed more hair growth in these regions when normally glaucoma patients on bimatoprost do not develop hair growth elsewhere.

The clinically observable eyelash hypertrichosis resolves following discontinuation of latanoprost or bimatoprost.^[10] However, persistent trichomegaly up to 14 months has been noted in some patients after a brief exposure to latanoprost.^[4] Our patient was switched to dorzolamide and timolol fixed combination in both the eyes (Dorzox T, Sun Pharma) and the regional hair growth reduced to a mild extent seven months after stopping bimatoprost. The further plan would be to consider filtering surgery if target pressures are not achieved.

In conclusion though eyelash growth and hirsutism are side effects of prostaglandin analogues, the former is a sign of femininity and beauty but the latter a cause for significant social and psychological stress. Doctors need to be aware of this potential side effect and exercise caution when considering prostaglandin analogues in the treatment of patients with already mild localized hypertrichosis and glaucoma.

REFERENCES

1. Cantor LB. Clinical pharmacology of bimatoprost. *Expert Opin Drug Metab Toxicol* 2005;1:151-7.
2. Lee AJ, McCluskey P. Clinical utility and differential effects of prostaglandin analogs in the management of raised intraocular pressure and ocular hypertension. *Clin Ophthalmol* 2010;4:741-64.
3. Peplinski LS, Albani Smith K. Deepening of lid sulcus from topical bimatoprost therapy. *Optom Vis Sci* 2004;81:574-7.
4. Johnstone MA, Albert DM. Prostaglandin-induced hair growth. *Surv Ophthalmol* 2002;47 (Suppl 1):S185-202.
5. DuBiner H, Cooke D, Dirks M, Stewart WC, VanDenburgh AM, Felix C. Efficacy and safety of bimatoprost in patients with elevated intraocular pressure: A 30-day comparison with latanoprost. *Surv Ophthalmol* 2001;45(Suppl 4):S353-60.
6. Brandt JD, VanDenburgh AM, Chen K, Whitcup SM; Bimatoprost Study Group. Comparison of once- or twice-daily bimatoprost with twice-daily timolol in patients with elevated IOP: A 3-month clinical trial. *Ophthalmology* 2001;108:1023-31; discussion 1032.
7. Bencini PL, Montagnino G, Sala F, De Vecchi A, Crosti C, Tarantino A. Cutaneous lesions in 67 cyclosporin-treated renal transplant recipients. *Dermatologica* 1986;172:24-30.
8. Tosi A, Misciali C, Piraccini BM, Peluso AM, Bardazzi F. Drug-induced hair loss and hair growth. Incidence, management and avoidance. *Drug Saf* 1994;10:310-7.
9. Ochoa BE, Sah D, Wang G, Stamper R, Price VH. Instilled bimatoprost ophthalmic solution in patients with eyelash alopecia areata. *J Am Acad Dermatol* 2009;61:530-2.
10. Johnstone MA. Hypertrichosis and increased pigmentation of eyelashes and adjacent hair in the region of the ipsilateral eyelids of patients treated with unilateral topical latanoprost. *Am J Ophthalmol* 1997;124:544-7.10.

How to cite this article: Kaliaperumal S, Govindaraj I, Kopparapu PK, Ahuja S. Hirsutism following the use of bimatoprost eyedrops for glaucoma. *J Pharmacol Pharmacother* 2014;5:208-10.

Source of Support: Nil, **Conflict of Interest:** None declared.

New features on the journal's website

Optimized content for mobile and hand-held devices

HTML pages have been optimized for mobile and other hand-held devices (such as iPad, Kindle, iPod) for faster browsing speed.

Click on **Mobile Full text** from Table of Contents page.

This is simple HTML version for faster download on mobiles (if viewed on desktop, it will be automatically redirected to full HTML version)

E-Pub for hand-held devices

EPUB is an open e-book standard recommended by The International Digital Publishing Forum which is designed for reflowable content i.e. the text display can be optimized for a particular display device.


Click on **Epub** from Table of Contents page.

There are various e-Pub readers such as for Windows: Digital Editions, OS X: Calibre/Bookworm, iPhone/iPod Touch/iPad: Stanza, and Linux: Calibre/Bookworm.

E-Book for desktop

One can also see the entire issue as printed here in a 'flip book' version on desktops.

Links are available from Current Issue as well as Archives pages.

Click on  View as eBook