

# Netilmicin-induced carpopedal spasm

Roja Y. Ramani, Benu Panigrahy<sup>1</sup>, Bandana Rath

Departments of Pharmacology and <sup>1</sup>Urology, Maharaja Krishna Chandra Gajapati Medical College and Hospital, Berhampur, Odisha, India

Received: 31-10-2013

Revised: 30-11-2013

Accepted: 08-02-2014

## ABSTRACT

Aminoglycoside-induced nephrotoxicity is not uncommon. Netilmicin being a member of gentamicin family has the advantage of being relatively free from ototoxicity and nephrotoxicity and is also prescribed for gentamicin resistant cases. In spite of these benefits with netilmicin, occasional development of symptomatic hypomagnesemia, hypocalcemia, and hypokalemia due to renal electrolyte wasting cannot be ruled out. Here we describe two cases of carpopedal spasm due to hypocalcemia following use of netilmicin.

**Key words:** Carpopedal spasm, hypocalcemia, netilmicin

## INTRODUCTION

Netilmicin, a semi-synthetic aminoglycoside, is highly effective against gram negative infections of the urinary tract (UTI), skin and skin structure (SSTI), and lower respiratory tract (RTI), as well as in intraabdominal infections and septicemia.<sup>[1]</sup> It has similar pharmacokinetic properties and dosage to that of gentamicin. Its major advantages are comparable or superior efficacy over other aminoglycosides, good clinical efficacy against gentamicin-resistant strains with relatively reduced ototoxicity and nephrotoxicity.<sup>[2-4]</sup> Hypocalcemia manifesting as carpopedal spasm with this drug has not been reported till date. Here we report two cases of carpopedal spasm following use of netilmicin prescribed for genitourinary surgery.

## CASE REPORTS

### Case 1

A 12-year-old boy had to undergo operative procedure for epispadias and was on surgical prophylaxis with netilmicin 150 mg i.v. twice daily and ceftriaxone (500 mg) i.v twice daily. The boy received both the drugs for 3 days (six doses) following which he developed severe spasm of the feet and hands [Figures 1-3]. On observation the patient was irritable, there was flexion of the hands at the wrists and of the fingers at the metacarpophalangeal joints and extension of the fingers at the inter-phalangeal joints; the feet were dorsiflexed at the ankles and the toes plantar flexed. Immediate laboratory investigation revealed the following picture: Serum calcium 7.2 mg/dL (normal, 8.7-11 mg/dL), potassium 3.9 mmol/L (normal, 3.5-5.5 mmol/L), and sodium of 145 mmol/L (normal, 135-155 mmol/L), serum creatinine 3.0 mg/dL and serum albumin 3.4 g/dL (normal, 3.8-4.4 g/dL) with normal urine output. Total bilirubin, serum glutamic oxaloacetic transaminase (SGOT), and serum glutamic-pyruvic transaminase (SGPT) were also normal. Assuming that the patient developed drug-induced nonoliguric renal failure; both the drugs were withdrawn and the surgery postponed. The hypocalcemia was managed

### Access this article online

#### Quick Response Code:



#### Website:

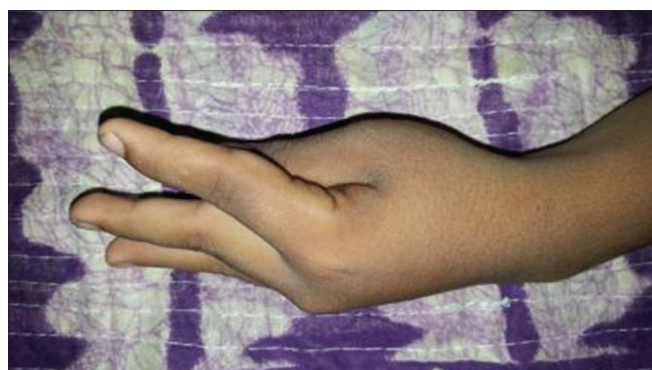
[www.jpharmacol.com](http://www.jpharmacol.com)

#### DOI:

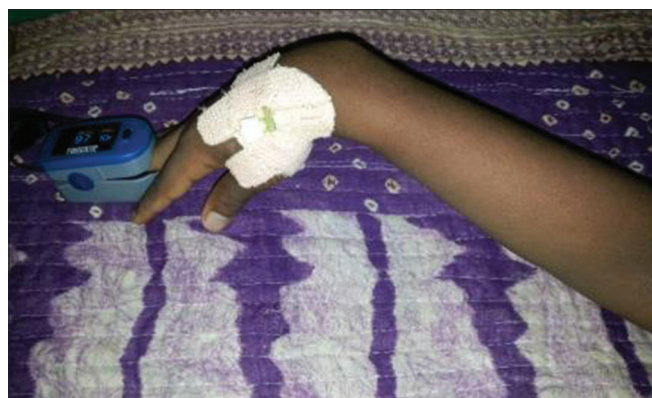10.4103/0976-500X.136112

### Address for correspondence:

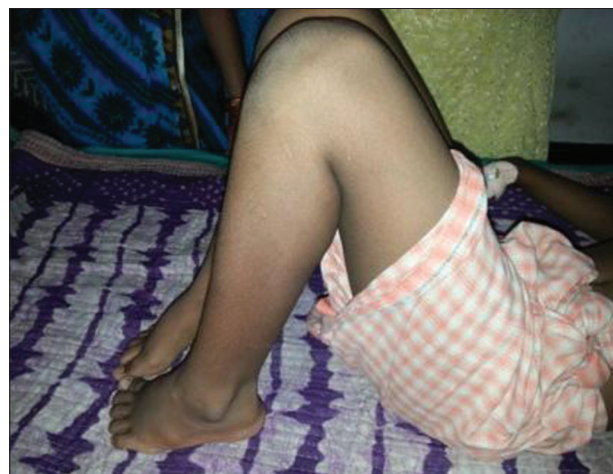Roja Y Ramani, Department of Pharmacology, Maharaja Krishna Chandra Gajapati Medical College, Berhampur, Orissa - 760 004, India.  
E-mail: [yrramani@gmail.com](mailto:yrramani@gmail.com)



**Figure 1:** Carpal spasm (left hand)



**Figure 2:** Carpal spasm (right hand)



**Figure 3:** Flexed legs

with i.v. calcium gluconate. 24 h following this episode the laboratory investigations were repeated, which showed serum calcium 9.3 mg/dL, potassium, 3.9 mmol/L, sodium 144 mmol/L and serum albumin 4.2 g/dL [Table 1]. On recovery, the patient was discharged with oral calcium supplementation. After 4 weeks the surgery was planned. Netilmicin 300 mg once daily was given preoperatively for 1 day and continued postoperatively. But after 3 days (4 doses) postoperatively the patient developed the same features of carpopedal spasm with laboratory findings of

**Table 1: Laboratory findings of netilmicin-induced carpopedal spasm**

Laboratory test	Case 1		Case 2	
	At the time of ADR	24 h post-ADR	At the time of ADR	24 h post-ADR
Biochemical				
Serum Ca <sup>2+</sup> (mg/dL)	7.2*	9.3	7.6*	9.8
Serum albumin (g/dL)	3.4*	4.2	3.2*	3.8
Serum creatinine (mg/dL)	3.0	2.0	2.5	1.0
Electrolyte (mmol/L)				
Serum Na <sup>+</sup>	144.0	146	138	136
Serum K <sup>+</sup>	3.9	4.1	3.5	3.7

\*Abnormal values

hypocalcemia. On withdrawal of netilmicin and calcium supplementation the boy recovered.

## Case 2

A 8-year-old boy diagnosed to be a case of hypospadias was given netilmicin 150 mg i.v. once daily as surgical prophylaxis for 2 days and was operated on the second day. Netilmicin in the same dose was continued postoperatively, but following the fifth dose, the child developed the characteristic features of tetany. Laboratory findings revealed low serum calcium (7.6 mg/dL), high serum creatinine (2.5 mg/dL) [Table 1]. Urine output was normal with serum electrolytes (Na<sup>+</sup> and K<sup>+</sup>) within the normal range. Assuming that the reaction was due to hypocalcemia induced by netilmicin, it was withdrawn and supplemented with piperacillin + tazobactam. The child recovered following i.v. administration of calcium gluconate.

## DISCUSSION

Carpopedal spasm (seen in tetany) is usually caused by low ionized serum calcium concentration, which causes increased excitability of peripheral nerves resulting in carpopedal spasm, convulsion, and stridor. The total serum calcium <8.5 mg/dL may be associated with tetany. We reported here two cases of carpopedal spasm caused by netilmicin.

A dose dependent nephrotoxicity occurs with aminoglycoside therapy despite adequate fluid volume control and drug level monitoring. Renal electrolyte wasting is occasionally caused by symptomatic hypomagnesemia, hypocalcemia, and hypokalemia when treated with these drugs<sup>[5]</sup> but tetany has not been frequently reported except for a single report on paramomycin.<sup>[6]</sup> Several risk factors, like volume depletion, sepsis, liver and renal dysfunction, hypokalemia, hypomagnesemia, advanced age, prolonged therapy, type of aminoglycoside, time and frequency of dosing, an elevated serum aminoglycoside concentration, and interactions with other nephrotoxic drugs such as vancomycin, amphotericin B,

piperacillin, cephalosporins, foscarnet, allopurinol, NSAIDs, inhibitors of angiotensin converting enzyme, cyclosporine, and cisplatin have been identified.<sup>[7,8]</sup> Among all aminoglycosides, netilmicin stands out clear because of its least toxicity and superior clinical efficacy, even in some resistant microorganisms.<sup>[3,9]</sup> Though studies show a clear benefit of the ceftriaxone-netilmicin combination,<sup>[10]</sup> their potential for interaction cannot be overlooked. Therefore netilmicin and ceftriaxone being nephrotoxic, both may be the suspects in the case report one. But it was also observed that, netilmicin prescribed alone in once daily dose later on (in case report one) and even half the dose (in case report two) also resulted in hypocalcemia and carpopedal spasm (tetany). In both the cases, laboratory findings with regard to serum electrolytes, urea, creatinine, albumin prior to administration of netilmicin were within normal range. Other causes of hypocalcemia like vitamin D deficiency, chronic renal failure, hypoparathyroidism were ruled out in both the cases. Another important point to be noted here that, though majority of patients in this hospital setup are being given netilmicin alone/netilmicin + ceftriaxone in combination, this type of adverse effects are seldom reported. Therefore netilmicin is probably the drug responsible for this rare adverse effect in these two cases (causality assessment using Naranjo's Adverse Drug Reaction probability score = score 7 and WHO-UMC causality assessment scale).

## CONCLUSION

Recent studies have emphasized the role of calcium in aminoglycoside-induced renal failure.<sup>[11]</sup> Netilmicin has long been used both alone and in combination with ceftriaxone in the adult and pediatric population for the treatment of severe gram negative infections in hospital settings. Judicious use of such drugs is required to prevent untoward side effects like tetany and its associated disability. Identifying high risk

patients and quick recognition of drug-induced injury with prompt cessation of the offending drug is the key to managing such cases before the injury causes permanent damage to the renal tissue.

## REFERENCES

1. Campoli-Richards DM, Chaplin S, Sayce RH, Goa KL. Netilmicin. A review of its antibacterial activity, pharmacokinetic properties and therapeutic use. *Drugs* 1989;38:703-56.
2. Panwalker AP, Malow JB, Zimelis VM, Jackson GG. Netilmicin: Clinical efficacy, tolerance, and toxicity. *Antimicrob Agents Chemother* 1978;13:170-6.
3. Buckwold FJ, Ronald AR, Lank B, Thompson L, Fox L, Harding GK. Clinical efficacy and toxicity of netilmicin in the treatment of gram-negative infections. *Can Med Assoc J* 1979;120:161-7.
4. Martínez-Salgado C, López-Hernández FJ, López-Novoa JM. Glomerular nephrotoxicity of aminoglycosides: Review. *Toxicol Appl Pharmacol* 2007;223:87.
5. Elliott C, Newman N, Madan A. Gentamicin effects on urinary electrolyte excretion in healthy subjects. *Clin Pharmacol Ther* 2000;67:16-21.
6. Thakur CP. Tetany in kala azar patients treated with paromomycin. *Indian J Med Res* 2008;127:489-93.
7. Bertino JS Jr, Booker LA, Franck PA, Jenkins PL, Franck KR, Nafziger AN. Incidence of and significant risk factors for aminoglycoside-associated nephrotoxicity in patients dosed by using individualized pharmacokinetic monitoring. *J Infect Dis* 1993;167:173-9.
8. Verpooten GA, Tulkens PM, Molitoris BA. Aminoglycosides and Vancomycin. *Clinical Nephrotoxins*. 2<sup>nd</sup> ed. Dordrecht, The Netherlands: Kluwer Academic Publishers; 2003. p. 151-62.
9. Kumana CR, Yuen KY. Parenteral aminoglycoside therapy. Selection, administration and monitoring. *Drugs* 1994;47:902-13.
10. Fantin B, Pangon B, Potel G, Vallois JM, Caron F, Bure A, *et al.* Ceftriaxone-netilmicin combination in single-daily-dose treatment of experimental *escherichia coli* endocarditis. *Antimicrob Agents Chemother* 1989;33:767-70.
11. Lortholary O, Blanchet F, Nochy D, Heudes D, Seta N, Amirault P, *et al.* Effects of diltiazem on netilmicin-induced nephrotoxicity in rabbits. *Antimicrob Agents Chemother* 1993;37:1790-8.

**How to cite this article:** Ramani RY, Panigrahy B, Rath B. Netilmicin-induced carpopedal spasm. *J Pharmacol Pharmacother* 2014;5:211-3.

**Source of Support:** Nil, **Conflict of Interest:** None declared.

## Staying in touch with the journal

### 1) Table of Contents (TOC) email alert

Receive an email alert containing the TOC when a new complete issue of the journal is made available online. To register for TOC alerts go to [www.jpharmacol.com/signup.asp](http://www.jpharmacol.com/signup.asp).

### 2) RSS feeds

Really Simple Syndication (RSS) helps you to get alerts on new publication right on your desktop without going to the journal's website. You need a software (e.g. RSSReader, Feed Demon, FeedReader, My Yahoo!, NewsGator and NewzCrawler) to get advantage of this tool. RSS feeds can also be read through FireFox or Microsoft Outlook 2007. Once any of these small (and mostly free) software is installed, add [www.jpharmacol.com/rssfeed.asp](http://www.jpharmacol.com/rssfeed.asp) as one of the feeds.