

Kounis syndrome secondary to intravenous cephalosporin administration

Sunkavalli Venkateswararao, Gopalan Rajendiran¹, Rathakrishnan Shanmuga Sundaram¹, Godavarthi Mounika

Department of Pharmacy Practice, PSG College of Pharmacy, ¹Department of Cardiology, PSG Institute of Medical Sciences and Research, Coimbatore, Tamil Nadu, India

Received: 03-10-2014

Revised: 25-05-2015

Accepted: 29-05-2015

ABSTRACT

Kounis syndrome is a clinical condition due to hypersensitivity that culminates into acute coronary syndrome (ACS) which can be fatal. A 36-year-old male with no conventional coronary risk factors presented elsewhere with a history of fever for 4 days, cough with expectoration, diarrhea and was treated with cephalosporin (Inj. Cefotaxime as an infusion) along with analgesics. He experienced generalized itching 5 minutes after cefotaxime infusion followed by sweating, headache, chest pain with facial and periorbital swelling for which he was rushed to our hospital. On examination he was afebrile with a low blood pressure. Electrocardiogram taken at an outside hospital revealed incomplete right bundle branch block and ST depression V3–V5. Investigations showed increase in troponin T. He was managed with anti-histamines and standard protocol for treatment of ACS. Coronary angiogram revealed normal coronaries. The patient improved symptomatically with treatment and was discharged on an anti-platelet, nitrate and a statin.

Key words: Acute coronary syndrome, cephalosporin, hypersensitivity, Kounis syndrome

INTRODUCTION

Kounis syndrome (KS) is defined as the concurrence of acute coronary syndrome (ACS) with conditions associated with mast cell activation relating to hypersensitivity.^[1] The incidence of KS is not established due to lack of well-defined studies to record the events; the available evidence is based on case series and case reports. Multiple agents have been described to trigger KS including drugs, contrast media, stent

material, insect stings, food, environmental exposures and medical conditions like asthma.^[1-3] Among drugs antibiotics were reported as important cause of KS. Here we report a case presented with features of anaphylactic reaction after cefotaxime injection and features of ACS, which was considered rare compared to other cephalosporins.

CASE REPORT

A 36-year-old male with no conventional coronary risk factors was treated elsewhere for fever, cough with expectoration and diarrhea with antibiotic (Inj. Cefotaxime 1 gm as an infusion) and analgesics. He experienced generalized itching 5 minutes after cefotaxime infusion along with sweating, headache, chest pain and facial swelling for which he was brought to our hospital. His medical records revealed the administration of corticosteroid (Betamethasone) injection along with analgesics

Access this article online	
Quick Response Code:	Website: www.jpharmacol.com
	DOI: 10.4103/0976-500X.171877

Address for correspondence:

G Rajendiran, Department of Cardiology, PSG Institute of Medical Sciences and Research, Coimbatore - 641 004, Tamil Nadu, India.
E-mail: rajeng68@gmail.com

after the onset of reaction. Five years ago he had hypersensitivity to an unknown tablet. On examination he was afebrile, mildly tachycardic and tachypneic with a blood pressure of 80/60 mmHg.

An electrocardiogram (ECG) taken immediately after the reaction and subsequent ECG taken at our hospital are similar and revealed sinus rhythm, ST depression V3–V5 and incomplete right bundle branch block, ST elevation-I, aVR [Figure 1]. Hemogram revealed relative neutrophilia (92.7%), normal ESR and eosinophil count with normal red blood cells. Serum electrolytes, creatinine and random blood sugar were normal while potassium was low (3.24 mEq/L). Arterial blood gases revealed mild hypocapnia [pCO₂-31.9 mmHg, pO₂-111.9 mmHg]. Troponin T was elevated (1027 pg/ml) and liver enzymes were slightly increased. The patient was immediately administered with intravenous antihistaminic, a H₂ receptor blocker, and an anti-emetic. He was started on a standard protocol for the management of ACS including dual anti-platelets, statin, betablocker, low-molecular-weight heparin after which the patient improved symptomatically. Echocardiogram showed good left ventricular (LV) systolic function with no regional wall motion abnormality (RWMA). A coronary angiogram performed on the subsequent day revealed normal epicardial coronaries with no evidence of spasm or thrombus. Work up for young myocardial infarction was negative with an exception of serum homocysteine levels (49.3 µmol/L). The patient was diagnosed with KS and was treated suitably which lead to his discharge after 4 days with an anti-platelet, nitrate and a statin.

DISCUSSION

Our case presented with ACS and anaphylactic reaction (caused by a previous antibiotic injection). Though an acute coronary event unrelated to anaphylaxis cannot be completely ruled out, totally asymptomatic state before the antibiotic administration,

chronology of events and normal coronaries favor ACS related to anaphylactic reaction possibly due to coronary vasospasm. A majority of case reports showed ECG abnormality as ST segment elevation, but in our case the ECG revealed ST depression.^[3,4]

Kounis and Zavras first described the simultaneous appearance of acute coronary events and anaphylactic reaction, called Kounis syndrome or allergic angina which could be due to coronary vasospasm or rupture of pre-existing atheromatous plaque.^[5]

Inflammatory mediators such as histamine, neutral proteases like chymase, tryptase, platelet-activating factor and variety of cytokines and chemokines constitute the pathophysiologic basis of KS.^[1-3,6] Histamine released during anaphylactic reaction acts on H₁ receptors causing coronary vasoconstriction and its action on H₂ and H₃ receptors causes hemodynamic instability. It also promotes platelet aggregation. Chymase converts angiotensin I into angiotensin II, which acts synergically with histamine upon receptors in the cells of coronary arteries, aggravating coronary spasm.^[2] Anaphylactic cardiac damage may be dissociated into two sets of events: (i) Initial primary cardiac reaction caused by the intracardiac release of histamine (ii) a subsequent cardiovascular reaction secondary to systemic release of mediators.^[1,7] Several antibiotics and few nonsteroidal anti-inflammatory drugs (NSAIDs) were reported as a cause of KS [Table 1].^[3,5,6]

Among third generation cephalosporins, cefotaxime rarely causes anaphylaxis yet in this case the patient was presented with severe anaphylaxis.^[8]

Majority of literatures identify three variants of Kounis syndrome that has been established. Type I includes patients with normal coronary arteries without predisposing factors for coronary artery disease (CAD), where the acute release

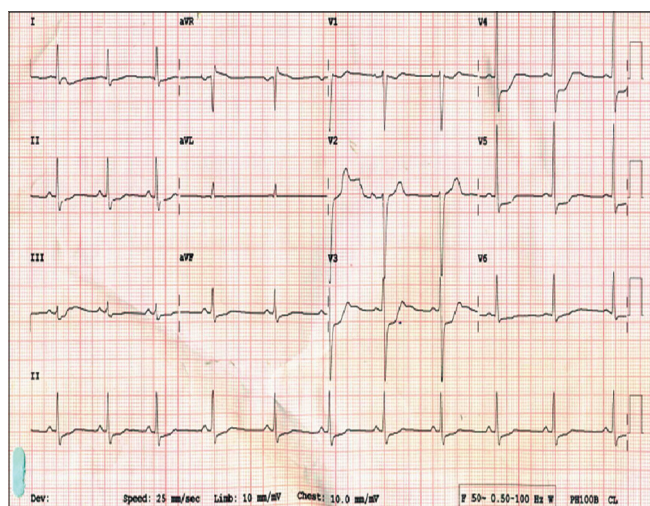


Figure 1: ECG showing abnormality after the reaction

Table 1: Antibiotics and NSAIDs reported to cause Kounis syndrome

Antibiotics	NSAIDs*
Penicillin G	Diclofenac sodium
Cefuroxime	Ibuprofen
Amoxicillin	Naproxen
Ampicillin-sulbactam	Aspirin
Cefoxitin	
Ciprofloxacin	
Amikacin	
Cefazolin	
Cephadrine	
Linomycin	
Vancomycin	

*NSAID=Nonsteroidal anti-inflammatory drugs

of inflammatory mediators can result in ACS with or without raised cardiac enzymes and troponins. Type II KS is a group with quiescent pre-existing atheromatous disease, in which the acute release of inflammatory mediators can result in ACS. Type III are patients with coronary artery thrombosis (including stent thrombosis) in whom aspirated thrombus specimens stained with hematoxylin-eosin and giemsa demonstrate the presence of eosinophils and mast cells.^[1-3,6] In this patient no coronary risk factors were identified except increase in serum homocysteine level. Elevated homocysteine level was reported as a risk factor for CAD, but a large meta analysis including prospective studies concluded that while serum homocysteine is elevated in patients with CAD, elevated homocysteine probably does not itself cause the disease.^[9] Thus, we classified our case as type I KS. Causality assessment of KS using Naranjo's algorithm, confirmed the event as "probable" adverse drug reaction.

Similar to the earlier published case reports relative neutrophilia and elevated troponin levels were observed in this patient also. There is no specific investigation to diagnose KS-associated ACS and treatment of KS involves administration of antihistamines, corticosteroids and/or ACS management protocol.^[4,10] A recent review reported that majority of the cases have been treated with corticosteroids (76%), H₁ blockers (70%), nitroglycerin (47%) and H₂ blockers (35%), while adrenalin was only used in 23% of the cases and aspirin in 18%.^[10]

CONCLUSION

Kounis syndrome is a clinical feature difficult to diagnose, but is important that a possibility of KS as a cause of acute coronary

syndrome be considered when patients present with features suggestive of anaphylactic reaction and ACS. Although a few cases of cephalosporin-related KS was reported, to the best of our knowledge, evidence of KS pertaining to cefotaxime was not recorded in earlier reports.

REFERENCES

1. Kounis NG. Coronary hypersensitivity disorder: The kounis syndrome. Clin Ther 2013;35:563-71.
2. Rico Cepeda P, Palencia Herrejón E, Rodríguez Aguirregabiria MM. Kounis syndrome. Med Intensiva 2012;36:358-64.
3. Laschos N, Tzerefos S, Katsaros A, Chrissos D. Kounis syndrome manifesting as acute st-segment elevation due to coronary vasospasm after cefuroxime-induced anaphylactic shock. Hosp Chron 2013;8:34-8.
4. Kounis NG, Soufras GD, Hahalis G. Anaphylactic shock: Kounis hypersensitivity-associated syndrome seems to be the primary cause. N Am J Med Sci 2013;5:631-6.
5. Kounis NG, Grapsas ND, Goudevenos JA. Unstable angina, allergic angina, and allergic myocardial infarction. Circulation 1999;100:e156.
6. Tiwari AK, Tomar GS, Ganguly S, Kapoor MC. Kounis syndrome resulting from anaphylaxis to diclofenac. Indian J Anaesth 2013;57:282-4.
7. Zavecz JH, Levi R. Separation of primary and secondary cardiovascular events in systemic anaphylaxis. Circ Res 1977;40:15-9.
8. Babu TA, Sharmila V. Cefotaxime-induced near-fatal anaphylaxis in a neonate: A case report and review of literature. Indian J Pharmacol 2011;43:611-2.
9. Christen WG, Ajani UA, Glynn RJ, Hennekens CH. Blood levels of homocysteine and increased risks of cardiovascular disease: Causal or casual? Arch Intern Med 2000;160:422-34.
10. Ridella M, Bagdure S, Nugent K, Cevik C. Kounis syndrome following beta-lactam antibiotic use: Review of literature. Inflamm Allergy Drug Targets 2009;8:11-6.

How to cite this article: Venkateswararao S, Rajendiran G, Sundaram RS, Mounika G. Kounis syndrome secondary to intravenous cephalosporin administration. J Pharmacol Pharmacother 2015;6:225-7.

Source of Support: Nil, **Conflict of Interest:** None declared.