

# QT interval prolongation and torsade de pointes: Synergistic effect of flecainide and H<sub>1</sub> receptor antagonists

Carlos Acosta-Materán, Eloy Díaz-Oliva, Diego Fernández-Rodríguez, Julio Hernández-Afonso

Department of Cardiology, Nuestra Señora de Candelaria University Hospital, Santa Cruz de Tenerife, Spain

Received: 05-05-2015

Revised: 29-05-2015

Accepted: 08-08-2015

## ABSTRACT

A high percentage of patients having atrial fibrillation (AF) presents with paroxysmal AF. Flecainide, the prototypic class Ic anti-arrhythmic drug is the most effective drug to maintain sinus rhythm in this subgroup of patients, though the drug has potential pro-arrhythmic effects. Furthermore, the H<sub>1</sub> receptor antagonists are the most commonly prescribed drugs for the symptomatic treatment of pruritus. Despite having low number of adverse effects, the H<sub>1</sub> receptor antagonists have cardiotoxic effects. Flecainide and H<sub>1</sub> receptor antagonists present arrhythmic complications including QT interval prolongation and torsade de pointes (TdP). The case presented here is a 65-year-old female who was diagnosed of atrial fibrillation and presented with rashes in lower extremities. The patient was treated using flecainide and H<sub>1</sub> receptor antagonists (loratadine and hydroxyzine) that prolonged QT interval and induced TdP. The concomitant administration of flecainide and H<sub>1</sub> receptor antagonists seems to have a synergistic effect in QT interval prolongation and subsequent TdP. The concurrent administration of H<sub>1</sub> receptor antagonists to patients receiving class Ic anti-arrhythmic drugs should be avoided in order to reduce arrhythmic risk in this population.

**Key words:** Arrhythmia, flecainide, H<sub>1</sub> receptor antagonist, QT interval

## INTRODUCTION

Atrial fibrillation (AF) is the most common sustained arrhythmia in adults, and a high percentage of these patients present with paroxysmal AF. Flecainide, a class Ic anti-arrhythmic drug is the

most effective drug to maintain sinus rhythm in this subgroup of population though the drug has potential pro-arrhythmic effects, including QT interval prolongation and ventricular tachycardia like torsade de pointes (TdP).<sup>[1]</sup> Furthermore, the H<sub>1</sub> receptor antagonists are the most commonly prescribed drugs for the symptomatic treatment of pruritus. Despite having low number of adverse effects, the H<sub>1</sub> receptor antagonists have cardiotoxic effects and they have been associated with QT interval prolongation and TdP.<sup>[2,3]</sup>

Access this article online	
Quick Response Code:	Website: www.jpharmacol.com
	DOI: 10.4103/0976-500X.184776

### Address for correspondence:

Diego Fernández-Rodríguez, Nuestra Señora de Candelaria University Hospital, Rosario Road 145, Santa Cruz de Tenerife - 38003, Spain. E-mail: dfernan2@clinic.ub.es

This is an open access article distributed under the terms of the Creative Commons Attribution-NonCommercial-ShareAlike 3.0 License, which allows others to remix, tweak, and build upon the work non-commercially, as long as the author is credited and the new creations are licensed under the identical terms.

**For reprints contact:** reprints@medknow.com

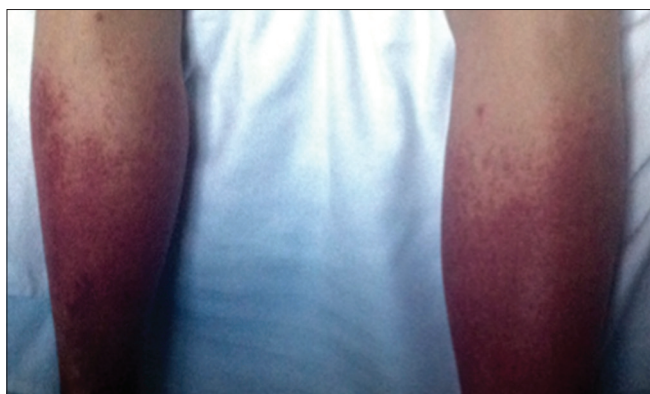**How to cite this article:** Acosta-Materán C, Díaz-Oliva E, Fernández-Rodríguez D, Hernández-Afonso J. QT interval prolongation and torsade de pointes: Synergistic effect of flecainide and H<sub>1</sub> receptor antagonists. J Pharmacol Pharmacother 2016;7:102-5.

The objective of this article is to describe the synergistic effect of flecainide and H<sub>1</sub> receptor antagonists in prolonging QT interval and inducing ventricular arrhythmias.

## CASE REPORT

A 65-year-old female patient was admitted to our institution with palpitations, progressive dyspnea accompanied by orthopnea and paroxysmal nocturnal dyspnea. The patient had a history of hypertension, dyslipidemia, diabetes mellitus, asthma, and paroxysmal AF, and was treated with amiodarone which was stopped because of hyperthyroidism.

Electrocardiogram demonstrated AF at 137 beats per minute, narrow QRS, and absence of repolarization abnormalities. The lung auscultation showed crepitant rales in both lower lung lobes, and the chest radiography showed signs of vascular redistribution. Transthoracic echocardiography (TTE) showed left and right ventricles of normal size and contractility, mild dilatation of the left atrium (44 mm), and no other relevant abnormalities.



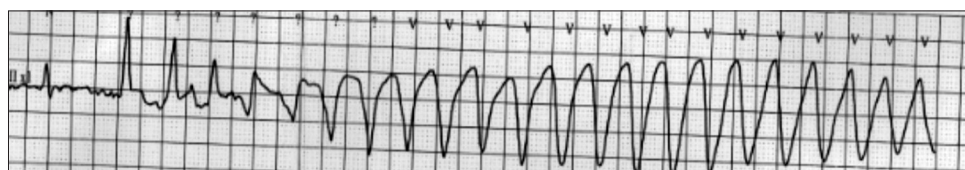
**Figure 1:** Rash in lower extremities

By treatment with parenteral anticoagulation and diuretics, the patient's condition was stabilized; congestive symptoms were controlled, spontaneously returning to sinus rhythm. After stabilization, bisoprolol (2.5 mg/12 h) and flecainide (50 mg/12 h) were initiated in order to maintain sinus rhythm. During hospitalization, the patient developed a pruriginous rash on lower extremities [Figure 1] that required treatment with oral H<sub>1</sub> receptor antagonists loratadine (10 mg/24 h) and hydroxyzine (25 mg/24 h), prolonging the hospital stay of the patient.

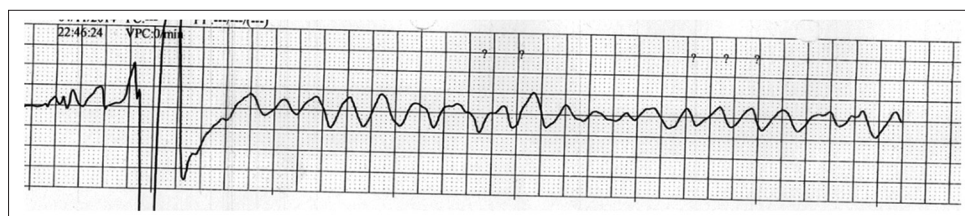
On the fourth day of concomitant therapy with flecainide and H<sub>1</sub> receptor antagonists, the patient had cardiac arrest secondary to TdP because of prolongation of QT interval that degenerated into ventricular fibrillation requiring cardiac defibrillation for six times, orotracheal intubation, and advanced cardiopulmonary resuscitation support, and the pulse recovered after 15 min [Figures 2–4]. Cranial computerized tomography scan revealed no intracranial bleeding or ischemic stroke and coronary angiography showed no significant coronary lesions. The patient presented a good recovery, being extubated 72 h after the cardiac arrest without neurologic sequelae. The patient presented again with AF and we opted for rate control strategy [Figure 5], initiating treatment with beta-blockers (bisoprolol 2.5 mg/12 h) for obtaining adequate heart rate. The patient was discharged and remains asymptomatic at 1 month follow-up.

## DISCUSSION

TdP is a polymorphic ventricular tachycardia syndrome that occurs in the context of long prolongation of the QT interval. This occurs because of the slowing of repolarization due to blockade of the delayed rectifier potassium current (IKr) producing prolongation of action potential. This slowing of



**Figure 2:** Electrocardiogram during cardiac arrest: Torsade de pointes



**Figure 3:** Electrocardiogram during cardiac arrest: Ventricular fibrillation

repolarization induces bradycardia and QT prolongation, predisposing to TdP.<sup>[4]</sup>

In accordance with clinical guidelines, flecainide is the preferred anti-arrhythmic drug in order to maintain sinus rhythm in patients with no structural heart disease because of its high rate of preserving sinus rhythm and low rate of adverse events in comparison with alternative drugs.<sup>[1]</sup> Nevertheless, flecainide, as an anti-arrhythmic drug presents with pro-arrhythmic effects previously identified in CAST trial<sup>[5]</sup> and experimental models of ischemia.<sup>[6]</sup> An increase in the rate of sudden death in patients taking flecainide was reported in the CAST trial,<sup>[5]</sup> principally related to QT interval prolongation and TdP.

The H<sub>1</sub> antagonist receptors have sedative and anti-cholinergic effects, and they even have potential cardiotoxic effects, including arrhythmic complications. The most frequent arrhythmogenic complications are palpitations and

extrasystoles. However, the H<sub>1</sub> receptor antagonists can cause malignant ventricular arrhythmias like TdP due to QT interval prolongation.<sup>[2,3,7]</sup>

The interaction between H<sub>1</sub> receptor antagonists and flecainide presents an exceptional occurrence and it has been very rarely reported. Although the management of these interactions is not reflected in clinical practice guidelines, the guidelines recommend that patients receiving flecainide or other class Ic anti-arrhythmic drugs must undergo strict control of QT interval.<sup>[1]</sup>

In addition, patients receiving H<sub>1</sub> receptor antagonists should stop using class Ic anti-arrhythmic drugs because of pruriginous rashes and be treated with alternative anti-arrhythmic drugs with neutral effects on the QT interval.<sup>[1]</sup> Furthermore, in rare cases where patients necessarily require continuing the treatment with flecainide, H<sub>1</sub> receptor antagonists could be replaced by corticosteroids.<sup>[8]</sup>

## CONCLUSION

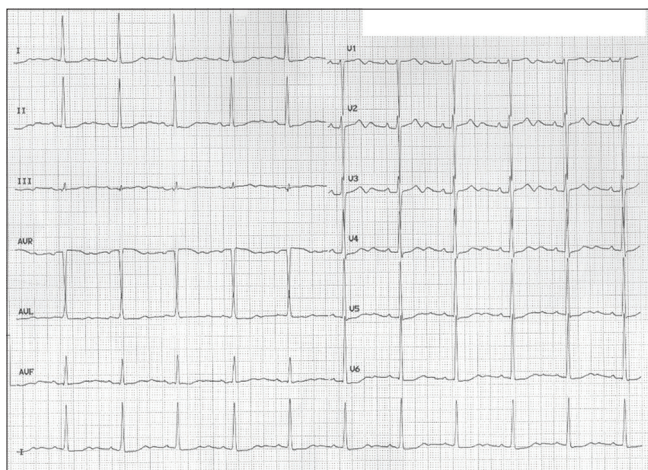
The concomitant administration of flecainide and H<sub>1</sub> receptor antagonists seems to have a synergistic effect in QT interval prolongation and subsequent TdP. The concurrent administration of H<sub>1</sub> receptor antagonists to patients receiving class Ic anti-arrhythmic drugs should be avoided in order to reduce arrhythmic risk in these patients.

## Financial support and sponsorship

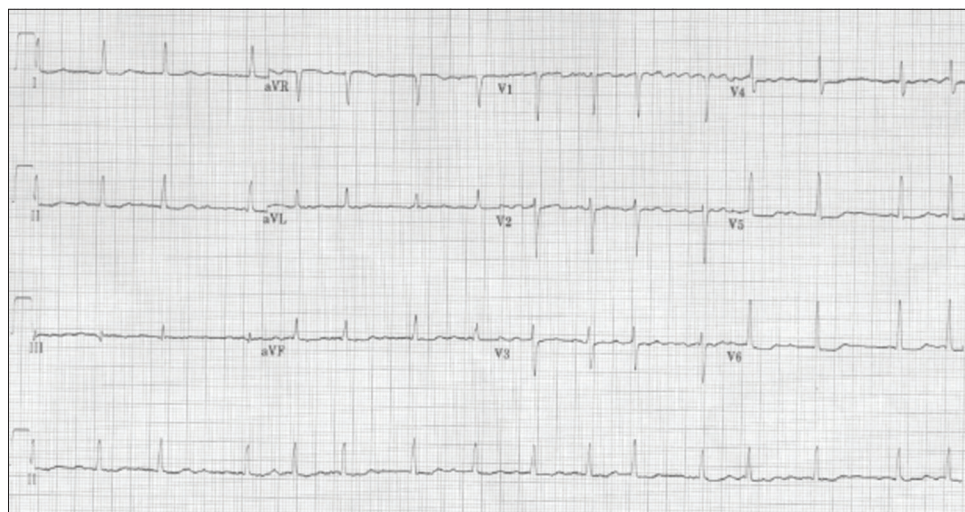
Nil.

## Conflicts of interest

There are no conflicts of interest.



**Figure 4:** Electrocardiogram immediately after cardiac arrest: Sinus rhythm with QT interval prolongation



**Figure 5:** Electrocardiogram after patient stabilization: Atrial fibrillation with absence of QT interval prolongation



## REFERENCES

1. Wann LS, Curtis AB, Ellenbogen KA, Estes NA, Ezekowitz MD, Jackman WM, *et al.*; American College of Cardiology Foundation; American Heart Association; European Society of Cardiology; Heart Rhythm Society. Management of patients with atrial fibrillation (compilation of 2006 ACCF/AHA/ESC and 2011 ACCF/AHA/HRS recommendations): A report of the American College of Cardiology/American Heart Association Task Force on practice guidelines. *Circulation* 2013;127:1916-26.
2. Leurs R, Church MK, Taglialatela M. H<sub>1</sub>-antihistamines: Inverse agonism, anti-inflammatory actions and cardiac effects. *Clin Exp Allergy* 2002;32:489-98.
3. Lu HR, Hermans AN, Gallacher DJ. Does terfenadine-induced ventricular tachycardia/fibrillation directly relate to its QT prolongation and Torsades de Pointes? *Br J Pharmacol* 2012;166:1490-502.
4. Lu HR, Rohrbacher J, Vlamincx E, Van Ammel K, Yan GX, Gallacher DJ. Predicting drug-induced slowing of conduction and pro-arrhythmia: Identifying the 'bad' sodium current blockers. *Br J Pharmacol* 2010;160:60-76.
5. Greenberg HM, Dwyer EM Jr, Hochman JS, Steinberg JS, Echt DS, Peters RW. Interaction of ischaemia and encainide/flecainide treatment: A proposed mechanism for the increased mortality in CAST I. *Br Heart J* 1995;74:631-5.
6. Brugada J, Boersma L, Kirchhof C, Allessie M. Proarrhythmic effects of flecainide. Experimental evidence for increased susceptibility to reentrant arrhythmias. *Circulation* 1991;84:1808-18.
7. Moneret-Vautrin DA, de Chillou C, Codreanu A. Long QT syndrome in a patient with allergic rhinoconjunctivitis and auto-immune diabetes: Focus on the choice of anti-H<sub>1</sub> drugs. *Eur Ann Allergy Clin Immunol* 2006;38:347-50.
8. Sidbury R, Davis DM, Cohen DE, Cordoro KM, Berger TG, Bergman JN, *et al.*; American Academy of Dermatology. Guidelines of care for the management of atopic dermatitis: Section 3. Management and treatment with phototherapy and systemic agents. *J Am Acad Dermatol* 2014;71:327-49.

### New features on the journal's website

#### Optimized content for mobile and hand-held devices

HTML pages have been optimized of mobile and other hand-held devices (such as iPad, Kindle, iPod) for faster browsing speed.

Click on **[Mobile Full text]** from Table of Contents page.

This is simple HTML version for faster download on mobiles (if viewed on desktop, it will be automatically redirected to full HTML version)

#### E-Pub for hand-held devices

EPUB is an open e-book standard recommended by The International Digital Publishing Forum which is designed for reflowable content i.e. the text display can be optimized for a particular display device.

Click on **[EPub]** from Table of Contents page.

There are various e-Pub readers such as for Windows: Digital Editions, OS X: Calibre/Bookworm, iPhone/iPod Touch/iPad: Stanza, and Linux: Calibre/Bookworm.

#### E-Book for desktop

One can also see the entire issue as printed here in a 'flip book' version on desktops.

Links are available from Current Issue as well as Archives pages.

Click on  View as eBook