

# Clozapine-induced cataract in a young female

Md. Shahid Alam, K. V. Praveen Kumar<sup>1</sup>

Department of Orbit Oculoplasty Reconstructive and Aesthetic Services, Sankara Nethralaya Medical Research Foundation, Chennai, Tamil Nadu, <sup>1</sup>Department of Ophthalmology, Narayana Medical College, Nellore, Andhra Pradesh, India

Received: 08-09-2016

Revised: 09-10-2016

Accepted: 13-10-2016

## ABSTRACT

A variety of systemic drugs including corticosteroids, amiodarone and antipsychotics have been known to cause cataract formation. Typical antipsychotics such as chlorpromazine have been reported to cause cataract formation in varying rates ranging from 22% to 80%. Cataract as an adverse effect resulting from the long term use of atypical antipsychotic has rarely been mentioned in literature, and there is only a single case report of cataract formation from prolonged use of clozapine. We report a rare case of clozapine induced cataract in a young female. The patient was advised to consult her psychiatrist for a change of drug and to undergo cataract surgery.

**Key words:** Atypical antipsychotic, cataract, clozapine

## INTRODUCTION

Cataract is defined as an opacity of the lens or its capsule and is the most common cause of preventable blindness worldwide.<sup>[1]</sup>

A variety of systemic drugs such as corticosteroids, amiodarone, and antipsychotics have been implicated in the causation of cataract. Ocular adverse effects in schizophrenic patients are mostly attributed to the use of phenothiazine group of antipsychotic medications. Greiner and Berry *et al.* in the mid-1960s first reported dense, dark brown lenticular opacities induced by phenothiazine use.<sup>[2]</sup>

Chlorpromazine, a typical antipsychotic drug has been reported to cause cataract in varying rates ranging from 22%

to 80%.<sup>[2]</sup> However, cataract formation as an adverse effect of atypical antipsychotics is less common and is rarely reported in literature. Cataract formation associated with the use of atypical antipsychotics has been reported with olanzapine, ziprasidone, and risperidone.<sup>[3]</sup> A thorough review of literature showed only a single case report of cataract caused by long-term use of clozapine, with no case been reported from India.<sup>[4]</sup> We herewith report a rare case of clozapine-induced cataract in a young Indian female.

## CASE REPORT

A 28-year-old female presented with complaints of gradually progressive diminution of vision in the right eye for the last 6 months. The patient was taking clozapine orally, 25 mg daily at bedtime for the past 1 year. The cumulative dose of the drug was 9.1 g.

On examination, the best-corrected visual acuity in the right eye was counting fingers at 2 m distance, and 6/9 in the left

Access this article online	
Quick Response Code:	Website: <a href="http://www.jpharmacol.com">www.jpharmacol.com</a>
	DOI: 10.4103/0976-500X.195904

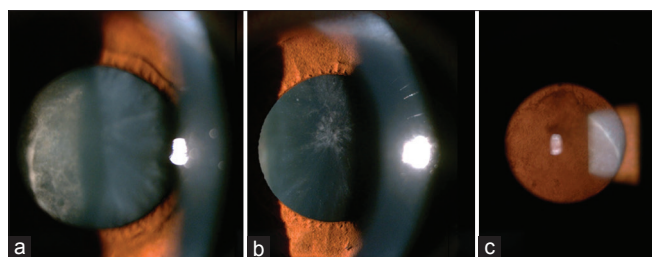
### Address for correspondence:

Md. Shahid Alam, Department of Orbit Oculoplasty Reconstructive and Aesthetic Services, Sankara Nethralaya Medical Research Foundation, Chennai, Tamil Nadu, India.  
E-mail: [mshahidalam@gmail.com](mailto:mshahidalam@gmail.com)

This is an open access article distributed under the terms of the Creative Commons Attribution-NonCommercial-ShareAlike 3.0 License, which allows others to remix, tweak, and build upon the work non-commercially, as long as the author is credited and the new creations are licensed under the identical terms.

**For reprints contact:** [reprints@medknow.com](mailto:reprints@medknow.com)

**How to cite this article:** Alam M, Praveen Kumar KV. Clozapine-induced cataract in a young female. J Pharmacol Pharmacother 2016;7:184-6.



**Figure 1:** (a) Slit lamp photograph (oblique illumination) of the right eye showing dense plaque-like posterior subcapsular cataract. (b) Slit lamp photograph (oblique illumination) of the left eye showing early posterior subcapsular cataract. (c) Slit lamp photograph (retroillumination) of the right eye showing dense posterior subcapsular cataract

eye. The cornea was clear in both eyes and there were no pigment deposits on the endothelium. Lens examination revealed a plaque-like posterior subcapsular cataract in the right eye and a faint early posterior subcapsular cataract in the left eye [Figure 1a-c]. Fundus examination of both eyes was unremarkable. On potential acuity meter testing, the visual acuity in the right eye improved to 6/9. There was no evidence of skin pigmentation. A presumptive diagnosis of clozapine-induced cataract was entertained and the patient was advised to consult the psychiatrist for alternative medication and to undergo cataract surgery in the right eye.

## DISCUSSION

Cataract is a degenerative process affecting elderly individuals. Causes of cataract developing in young individuals include congenital and developmental cataract, trauma, and systemic disorders such as diabetes mellitus, complicated cataract secondary to ocular diseases such as chronic uveitis, retinitis pigmentosa, high myopia, and long-term usage of drugs such as steroids, amiodarone, and phenothiazines.<sup>[5]</sup> As this patient had no signs of other ocular and systemic disorders, long-term use of clozapine could have been the only causative factor inducing cataract in her.

Long-term phenothiazine use is known to cause pigment deposits in the cornea, lens, and skin.<sup>[2]</sup> The etiology of phenothiazine-related ocular side effects is not clearly understood. Photosensitization of tissue proteins occurs in areas with increased sun exposure after accumulation of the drug in ocular tissues.<sup>[6]</sup>

Phenothiazines can also interact with melanin in the choriocapillaris and in the retinal pigment epithelium, inducing damage to the photoreceptors. Altered dopaminergic regulation of melatonin is supposed to make photoreceptors more susceptible to phototoxic damage. However, similar ocular side effects resulting from the use of atypical antipsychotics have rarely been reported in literature.

Clozapine is a tricyclic dibenzodiazepine with dopamine-receptor blocking property. It is an atypical antipsychotic that can be used as an alternative for phenothiazines, in refractory schizophrenia. Since it has got similar dopamine-receptor blocking property as that of phenothiazines, it is possible that clozapine might also lead to altered dopaminergic regulation of melatonin, causing similar adverse effects.

Souza *et al.* in their study on the development of cataract in patients on antipsychotic medications found that 18% of patients on atypical antipsychotics went on to develop cataract. However, none of the patients who developed cataract in their study was on clozapine.<sup>[3]</sup>

We herewith report the second case of clozapine-induced cataract and the first to report from India. Borovik *et al.* were the first to report a case of clozapine-induced lenticular opacities. Their patient also had associated pigment deposits on the corneal endothelium and anterior lens capsule along with pigmentary retinopathy. Although our patient did not have any evidence of ocular pigmentation, the nature of cataract, i.e., posterior subcapsular, was similar as reported by them. The difference in the findings can be explained by the fact that the cumulative dose and duration of usage of the drug were different in both the patients. Our patient was on clozapine for 1 year and the cumulative dose was 9.1 g as compared to the patient reported by Borovik *et al.* where the patient was on the drug for 16 years and cumulative dose was 4.67 kg. Since the cumulative dose of clozapine in our case was quite low, and we did not notice any associated pigment deposition either; the mechanism of developing cataract is difficult to explain. However, an association of long-term usage of clozapine, without the presence of other causative factors, strongly suggests the case to be drug induced.

Cataract should be considered as a possible side effect of clozapine use, particularly when used in young individuals and patient should be informed regarding the same before starting the drug. We recommend regular comprehensive ophthalmic examination in all patients who are on long-term clozapine therapy.

## Financial support and sponsorship

Nil.

## Conflicts of interest

There are no conflicts of interest.

## REFERENCES

1. Brian G, Taylor H. Cataract blindness – Challenges for the 21<sup>st</sup> century. Bull World Health Organ 2001;79:249-56.

### Alam and Kumar: Clozapine induced cataract

2. Greiner AC, Berry K. Skin pigmentation and corneal and lens opacities with prolonged chlorpromazine therapy. *Can Med Assoc J* 1964;90:663-5.
3. Souza VB, Moura Filho FJ, Souza FG, Rocha CF, Furtado FA, Gonçalves TB, *et al*. Cataract occurrence in patients treated with antipsychotic drugs. *Rev Bras Psiquiatr* 2008;30:222-6.
4. Borovik AM, Bosch MM, Watson SL. Ocular pigmentation associated with clozapine. *Med J Aust* 2009;190:210-1.
5. Yanoff M, Duker JS, editors. The lens. In: *Ophthalmology*. 3<sup>rd</sup> ed. St. Louisosby International Ltd.; 2004. p. 381.
6. Deluise VP, Flynn JT. Asymmetric anterior segment changes induced by chlorpromazine. *Ann Ophthalmol* 1981;13:953-5.