

Complete Response to Afatinib in Lung Adenocarcinoma of Epidermal Growth Factor Receptor Exon-19 Deletion Mutation and Disease Recurrence on Drug Discontinuation

Rashmi Kumari, Emmanuel James, K. Pavithran¹

Department of Pharmacy Practice, Amrita School of Pharmacy, Amrita Vishwa Vidyapeetham, Health Science Campus, ¹Department of Medical Oncology and Hematology, Amrita Institute of Medical Sciences and Research Centre, Amrita Vishwa Vidyapeetham, Health Science Campus, Kochi, Kerala, India

Abstract

Lung adenocarcinoma, the most widespread cause of neoplasm associated mortality in both men and women worldwide, is a subtype of non-small cell lung cancer (NSCLC). We address here the case of a 62-year-old female presented with symptoms of cough and breathlessness of 2-months duration. Histopathological examination of lung biopsy and immunohistochemical tests revealed lung adenocarcinoma. Integrated positron emission tomography-computed tomography (PET-CT) scan suggested right lung lesion with stage 4 (T3N3M1b) disease. Epidermal growth factor receptor (EGFR) mutation analysis was positive for exon-19 deletion mutation, and she was started on afatinib 40 mg once daily. PET-CT scan, at 6-months follow-up, was suggestive of complete response to therapy. Due to drug-induced persistent diarrhea, afatinib was discontinued by the patient, but a repeat PET-CT scan 6 months after discontinuation of treatment suggested disease recurrence. However, T790M-resistant mutation analysis was found to be negative, and she was restarted on afatinib at 30 mg once daily to minimize the drug-related diarrhea. After 15 months of afatinib therapy at reduced dosage, reevaluation by PET-CT suggested disease progression. Although afatinib monotherapy is effective in EGFR exon-19 deletion mutation NSCLC, this report suggests that discontinuation of the drug can lead to disease recurrence, and reducing the drug dose is not beneficial once disease recurrence occurs. To the best of our knowledge, this is the first reported case from India of advanced lung adenocarcinoma of EGFR exon-19 deletion showing a complete response to afatinib and recurrence of the disease after discontinuation of drug.

Keywords: Afatinib, disease recurrence, epidermal growth factor receptor, exon-19 deletion mutation, non-small cell lung adenocarcinoma

INTRODUCTION

Lung adenocarcinoma, the most widespread cause of neoplasm associated mortality in both men and women worldwide, is a subtype of non-small cell lung cancer (NSCLC).^[1] Almost 80%–85% of all lung adenocarcinomas are diagnosed with NSCLC.^[2] Smoking is a widely-known risk factor of lung adenocarcinoma, but even in nonsmokers, there is a high prevalence of targetable mutations of NSCLC.^[3] Mutations of Kirsten rat sarcoma viral oncogene, epidermal growth factor receptor (EGFR) gene and v-Raf murine sarcoma viral oncogene are involved in the development and advancement of NSCLC.^[4] EGFR is a tyrosine kinase receptor commonly activated in lung adenocarcinoma due to deletion mutation in exon-19 or substitution mutation in exon-21 (L858R

mutation, substitution at position 858 in EGFR from leucine to arginine).^[5] These mutations occur in approximately 30%–40% of NSCLC cases.^[6] Mutations of EGFR gene are more frequent in Asian females and nonsmokers.^[5] EGFR-targeted treatment is effective in advanced NSCLC patients with related gene mutations. Lung adenocarcinoma patients with EGFR mutations usually react well to EGFR

Address for correspondence: Emmanuel James,
Department of Pharmacy Practice, Amrita School of Pharmacy, Amrita
Vishwa Vidyapeetham, Health Science Campus, Kochi - 682 041,
Kerala, India.
E-mail: emmanuelj@aims.amrita.edu

This is an open access journal, and articles are distributed under the terms of the Creative Commons Attribution-NonCommercial-ShareAlike 4.0 License, which allows others to remix, tweak, and build upon the work non-commercially, as long as appropriate credit is given and the new creations are licensed under the identical terms.

For reprints contact: reprints@medknow.com

How to cite this article: Kumari R, James E, Pavithran K. Complete response to afatinib in lung adenocarcinoma of epidermal growth factor receptor exon-19 deletion mutation and disease recurrence on drug discontinuation. *J Pharmacol Pharmacother* 2018;9:191-4.

Received: 21-09-2018 **Revised:** 02-11-2018 **Accepted:** 27-11-2018

Access this article online

Quick Response Code:



Website:
www.jpharmacol.com

DOI:
10.4103/jpp.JPP_111_18

tyrosine kinase inhibitors (TKIs) which interrupt the signaling pathway of the EGFR.^[7] For patients with EGFR-mutated metastatic NSCLC, first-generation reversible TKIs (gefitinib or erlotinib) or second-generation irreversible TKIs (afatinib) are used as first-line therapy. Afatinib is an orally bioavailable aniline-quinazoline derivative and an inhibitor of the receptor tyrosine kinase (RTK) EGFR family with antineoplastic activity. Afatinib selectively and irreversibly binds and inhibits the EGFR1 (ErbB1), HER2 (ErbB2, human EGFR [HER]) and HER4 (ErbB4) receptors and certain EGFR mutants including those caused by EGFR exon-19 deletion mutations or exon-21 substitution (L858R) mutation. EGFR, HER2, and HER4 are RTKs belonging to the EGFR superfamily and play a major role in tumor cell proliferation and are expressed in many malignant cell types. Afatinib also inhibits the EGFR T790M gatekeeper mutation which is resistant to treatment with first-generation EGFR inhibitors. Afatinib was approved by the US Food and Drug Administration (FDA) in July 2013 for treatment of metastatic lung cancer with EGFR exon-19 deletion or exon-21 substitution mutation. The drug has a half-life of 37 h and is given once daily at a dose of 40 mg.^[3] Here, we address a case of NSCLC with EGFR exon-19 deletion mutation in an Indian lady who was treated with afatinib.

CASE REPORT

A 62-year-old female nonsmoker was referred to our institution in June 2015 with the symptoms of cough and breathlessness (no cardiovascular symptoms) of 2-months duration. She was evaluated elsewhere with computed tomography (CT) of chest showing space-occupying lesion in the upper lobe of the right lung with mediastinal lymphadenopathy.

Lung biopsy from our institution revealed lung carcinoma with cores of fibrocollagenous tissue with an invasive neoplasm composed of cells arranged in nests and focally in glandular pattern. Many cells had pleomorphic vesicular nuclei, and moderate cytoplasm with irregular margins and mitosis was also seen. Immunohistochemical test revealed positive cells for carcinoembryonic antigen, cytokeratin 7, high molecular weight cytokeratin, and thyroid transcription factor 1 suggestive of adenocarcinoma.

Positron emission tomography-CT (PET-CT) scan of whole body suggested increased ¹⁸F-fluorodeoxyglucose (FDG) uptake [Figure 1a] in the upper lobe of right lung (3.3 [AP] × 2.5 [TR] × 3.7 [CC] cm with pleural tags and abutting the apical visceral pleura), lymph nodes (bilateral cervical level nodules [right lower paratracheal (12 mm × 9 mm), right upper paratracheal (8 mm × 9 mm), bilateral hilar (left: 9 mm × 8 mm, right: 10 mm × 8 mm)]), nodules in left lobe of thyroid gland (13 mm × 8 mm), multiple pulmonary nodules (largest in right lung measuring 12 mm × 12 mm), and medial limb of left adrenal gland appeared bulky, all suggestive of lung malignancy^[8] with lymph nodal and distant metastasis, indicating stage 4 (T2N3M1b) disease. EGFR mutation analysis showed EGFR exon-19 deletion

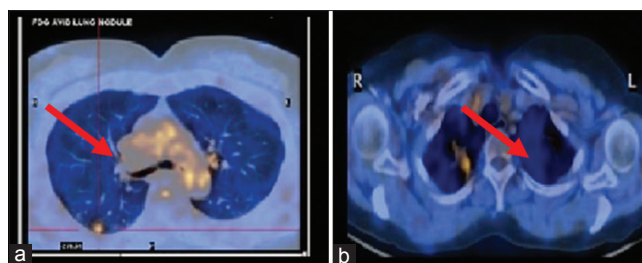


Figure 1: Positron emission tomography-computed tomography images showing. (a) Abnormal fluorodeoxyglucose uptake (pointed arrow) before afatinib treatment and (b) normal fluorodeoxyglucose uptake after 6 months of afatinib treatment at 40 mg once daily

mutation to be positive. In July 2015, the patient was started on afatinib (40 mg, once daily on empty stomach).

After 6 months of afatinib treatment at 40 mg daily dose, in January 2016, whole-body PET scan demonstrated complete metabolic resolution of malignancy with significant reduction in tumor size and number of nodules (upper lobe of right lung lesion [2.6 cm × 1.9 cm], nodules in left lobe of thyroid gland [13 mm × 8 mm]) remained status quo and no abnormal FDG uptake [Figure 1b]. Overall PET-CT findings were suggestive of good response to therapy. Based on response evaluation criteria in solid tumor guidelines version 1.1,^[9] this patient was considered to have complete response to afatinib. During afatinib treatment, her hepatic and renal functions were normal, and she was not on any other medications. The patient remained asymptomatic regard to lung adenocarcinoma but due to treatment-related adverse effect (Grade 3 diarrhea), she discontinued afatinib on her own in May 2016.

However, in November 2016, due to discontinuation of drug, her disease showed signs of recurrence with the symptoms of cough and dyspnea. The whole-body PET-CT scan showed that right lung upper lobe apical segment residual lesion remained status quo, measuring (2.6 cm × 1.9 cm) with the pleural tags and apical visceral pleura, suggestive of right lung malignancy with increase in tumor size, increase in number of multiple nodules and abnormal FDG uptake [Figure 2a] of bilateral pulmonary nodules (largest in posterior basal segment of right lung lower lobe 14 mm × 12 mm) indicating pulmonary metastasis, but no lymph nodal and distant metastasis were observed. Thus, PET-CT scan suggested disease recurrence. T790M resistance mutation was found to be negative. Hence, she was restarted on afatinib but at a lower dose (30 mg) to minimize the drug-related adverse effect. After 15 months of afatinib therapy at 30 mg daily dose, at follow-up visit, the whole-body PET-CT scan showed abnormal FDG uptake [Figure 2b] in the apical segment of right lung upper lobe which has increased in size (2.4 cm × 2.5 cm), and multiple nodules of varying sizes were seen distributed through both lung fields (all lobes, largest in right lung posterior basal segment measuring 3.7 cm × 6.4 cm) as well as lymph nodes at subcarinal (18 mm × 11 mm) and left hilar (16 mm × 13 mm)

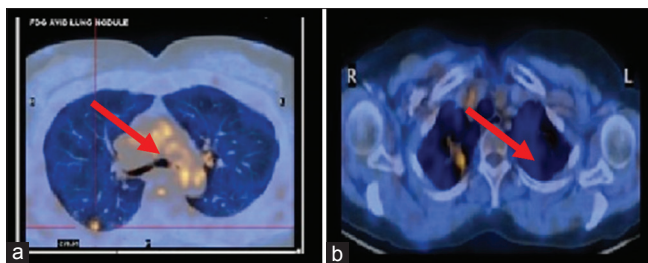


Figure 2: Positron emission tomography-computed tomography images showing abnormal fluorodeoxyglucose G uptake (pointed arrow). (a) Six months after discontinuation of afatinib and (b) after 15 months of afatinib treatment at 30 mg once daily

all suggestive of residual primary right lung malignancy, pulmonary, and lymph nodal metastasis.

DISCUSSION

NSCLC is a life-threatening disease, and complete cure of stage 4 NSCLC is difficult even with current modalities of treatment.^[10] Earlier, platinum-based chemotherapy was the therapeutic option for metastatic NSCLC. Later, understanding of different gene mutations involved in NSCLC led to the advancement of novel molecular targeted therapy.^[11] First-generation reversible EGFR TKIs and second-generation irreversible EGFR TKIs can be used as a first-line agents for patients with stage 4 NSCLC who is confirmed positive for EGFR mutation.^[12] Afatinib also inhibits the tumors caused by the oncogene HER2. Several patients establish resistance to the first-generation reversible TKIs, whereas afatinib overcomes the problem of resistance to erlotinib and gefitinib by blocking the dimerization of EGFR with HER2 which forms important rationale for overcoming resistance after therapy with first-generation EGFR TKIs.^[1] In April 2016, US FDA approved afatinib, also for patients with squamous cell neoplasm of the lung.^[5] European organization for research and treatment of cancer (EORTC) has reported better quality of life with patients on afatinib compared to patients receiving chemotherapy when measured using EORTC quality of research questionnaire C-303. As per a case series report,^[13] afatinib was also effective for the management of metastatic brain lesion with lung adenocarcinoma. Randomized controlled trial^[14] has shown better quality of life, higher objective response rate, and longer median progression-free survival (PFS) compared to standard platinum-based chemotherapy in NSCLC patients with EGFR mutation receiving EGFR TKIs. Median PFS of 13.6 months for afatinib versus 6.9 months for platinum-based chemotherapy and overall survival of 27.3 months for afatinib and 24.3 months for chemotherapy were reported.^[15] Therefore, afatinib is superior to platinum-based chemotherapy as a first-line therapy. Patients of EGFR exon-19 deletion NSCLC were observed to have greater benefit with afatinib compared to first-generation TKIs (erlotinib and gefitinib) as well as patients with EGFR L858R substitution mutations.^[3] A 73-year-old female with EGFR mutation with advanced NSCLC showed long PFS and stable disease with afatinib after

erlotinib failure.^[8] A recent report^[16] from Italy showed that a 71-year-old female patient with EGFR-mutated metastatic NSCLC achieved complete response with afatinib although the dose had to be reduced from 40 mg to 20 mg after she developed skin-related toxicity with the standard dose. Our patient was receiving the standard dose of afatinib, but the patient herself discontinued the drug due to intolerable diarrhea. Later, due to disease recurrence, the patient was restarted on afatinib at a lower dose of 30 mg without any appreciable adverse effects. Hence, this may be a suitable strategy for those who develop intolerable side effects with the use of 40 mg. Recommended treatment duration of afatinib is until disease progression or no longer tolerated by the patient.^[17] Discontinuation of drug for 14 days or dosage reduction is recommended in patients with intolerable adverse effects.^[16] In our case, discontinuation of the drug for a longer period (6 months) led to disease recurrence. The adverse effect of diarrhea was well controlled with the antidiarrheal drug (loperamide) in a 53-year-old Japanese male who was successfully treated with afatinib 40 mg daily for pancreatic metastasis of lung adenocarcinoma (EGFR exon-19 deletion mutation).^[18] However, in our patient, this was not attempted because the patient herself discontinued the drug without the knowledge of the physician. Thus, afatinib patients should be warned about this adverse effect, and such patients should be advised to consult their health-care provider before discontinuation of the drug. The common adverse effects^[4] of afatinib are gastrointestinal (diarrhea, nausea, vomiting, loss of appetite, and stomatitis) and dermatological reactions (skin rashes, dryness, itching, acne, and nail infection) of which severe diarrhea was observed in our patient. An observational study^[17] from Japan has shown partial response rate of 80% with afatinib as first-line agent, whereas 27.1% as second-line agent (after gefitinib and erlotinib failure) with no complete response. An independent review of afatinib as first-line agent in Asian patients with metastatic NSCLC EGFR mutations complete response rate was observed only in 1.2% of patients.^[19] To the best of our knowledge, this is the first reported case from India of advanced lung adenocarcinoma of EGFR exon-19 deletion showing a complete response to afatinib at the recommended dose and later led to recurrence of disease after discontinuation of treatment.

CONCLUSION

The patient we reported here with the EGFR exon-19 deletion lung adenocarcinoma achieved complete response with the recommended dose of afatinib. Hence, afatinib monotherapy as first-line treatment seems to be effective in the management of metastatic NSCLC. This report also suggests that even after achieving the complete response long-term discontinuation of drug can lead to disease recurrence. Although dose reduction can minimize the drug-related adverse effect, reducing the drug dose may not be beneficial in case of disease recurrence.

Declaration of patient consent

The authors certify that they have obtained all appropriate patient consent forms. In the form, the patient has given her

consent for her images and other clinical information to be reported in the journal. The patient understands that name and initials will not be published and due efforts will be made to conceal identity, but anonymity cannot be guaranteed.

Financial support and sponsorship

Nil.

Conflicts of interest

There are no conflicts of interest.

REFERENCES

1. Siegelin MD, Borczuk AC. Epidermal growth factor receptor mutations in lung adenocarcinoma. *Lab Invest* 2014;94:129-37.
2. Joshua JM, Salima KD, Pavithran K, Vijayan M. Crizotinib, an effective agent in ROS1-rearranged adenocarcinoma of lungs: A case report. *Clin Med Insights Case Rep* 2018;11:1179547617749615.
3. Köhler J, Schuler M. Afatinib, erlotinib and gefitinib in the first-line therapy of EGFR mutation-positive lung adenocarcinoma: A review. *Onkologie* 2013;36:510-8.
4. Joshi M, Rizvi SM, Belani CP. Afatinib for the treatment of metastatic non-small cell lung cancer. *Cancer Manag Res* 2015;7:75-82.
5. Mitsudomi T. Molecular epidemiology of lung cancer and geographic variations with special reference to EGFR mutations. *Transl Lung Cancer Res* 2014;3:205-11.
6. Sequist LV, Bell DW, Lynch TJ, Haber DA. Molecular predictors of response to epidermal growth factor receptor antagonists in non-small-cell lung cancer. *J Clin Oncol* 2007;25:587-95.
7. Vitale MG, Scagliarini S, Riccardi F, Barbato C, Otero M, Mocerino C, *et al.* Long progression-free survival with afatinib in a patient with EGFR-unknown lung adenocarcinoma after erlotinib failure: A case report. *Tumori* 2015;101:e64-6.
8. Padma S, Sundaram PS, George S. Role of positron emission tomography computed tomography in carcinoma lung evaluation. *J Cancer Res Ther* 2011;7:128-34.
9. Eisenhauer EA, Therasse P, Bogaerts J, Schwartz LH, Sargent D, Ford R, *et al.* New response evaluation criteria in solid tumours: Revised RECIST guideline (version 1.1). *Eur J Cancer* 2009;45:228-47.
10. Jiang H, Li MM, Jin SX. Anaplastic lymphoma kinase-positive lung adenocarcinoma patient with development of sick sinus syndrome while on targeted treatment with crizotinib. *J Thorac Dis* 2015;7:E19-22.
11. Yu JY, Yu SF, Wang SH, Bai H, Zhao J, An TT, *et al.* Clinical outcomes of EGFR-TKI treatment and genetic heterogeneity in lung adenocarcinoma patients with EGFR mutations on exons 19 and 21. *Chin J Cancer* 2016;35:30.
12. Mehta AA, Jose WM, Pavithran K, Triavadi GS. The role of gefitinib in patients with non-small-cell lung cancer in India. *Indian J Palliat Care* 2013;19:48-53.
13. Li SH, Hsieh MH, Fang YF. Afatinib in treatment-naive patients with EGFR-mutated lung adenocarcinoma with brain metastasis: A case series. *Medicine (Baltimore)* 2015;94:e1739.
14. Han JY, Park K, Kim SW, Lee DH, Kim HY, Kim HT, *et al.* First-SIGNAL: First-line single-agent iressa versus gemcitabine and cisplatin trial in never-smokers with adenocarcinoma of the lung. *J Clin Oncol* 2012;30:1122-8.
15. Yang JC, Wu YL, Schuler M, Sebastian M, Popat S, Yamamoto N, *et al.* Afatinib versus cisplatin-based chemotherapy for EGFR mutation-positive lung adenocarcinoma (LUX-lung 3 and LUX-lung 6): Analysis of overall survival data from two randomised, phase 3 trials. *Lancet Oncol* 2015;16:141-51.
16. Giusti R, Mazzotta M, Iacono D, Lauro S, Marchetti P. Complete tumor response with afatinib 20 mg daily in EGFR-mutated non-small cell lung cancer: A case report. *Clin Drug Investig* 2017;37:581-5.
17. Wada Y, Koyama S, Kuraishi H, Miyahara T, Yoshiike F, Agatsuma T, *et al.* Clinical analysis of patients treated with afatinib for advanced non-small cell lung cancer: A Nagano Lung Cancer Research Group observational study. *Respir Investig* 2016;54:462-7.
18. Furuya T, Shimada J, Okada S, Tsunozuka H, Kato D, Inoue M, *et al.* Successful treatment with afatinib for pancreatic metastasis of lung adenocarcinoma: A case report. *J Thorac Dis* 2017;9:E890-E893.
19. Wu YL, Zhou C, Hu CP, Feng J, Lu S, Huang Y, *et al.* Afatinib versus cisplatin plus gemcitabine for first-line treatment of Asian patients with advanced non-small-cell lung cancer harbouring EGFR mutations (LUX-lung 6): An open-label, randomised phase 3 trial. *Lancet Oncol* 2014;15:213-22.